

## Evaluation of Nutrient Foramen of the Femur, Tibia, and Fibula Bones in Center of Iran

### Abstract

**Background:** Nutritional arteries are the main source of blood supply to long bones. These foramina enable the blood vessels and nerves to pass through the cortex of the bone. The exact location and distribution of nutrient foramina are important for preventing damage to blood vessels and maintaining blood circulation during various surgical procedures. While inheritance and race are among the most effective factors in the distribution of these foramina, no relevant study has been conducted in Iran. Therefore, we aimed to evaluate this issue in Iran and find differences in comparison with other studies.

**Methods:** This study was performed on 157 lower limb bones present in moulage hall in the school of medicine, including long bones of the femur (N=65), tibia (N=65) and fibula (N=27).

**Results:** In this study, 39.09% of the femurs had two nutrient foramina, 90.78% of the tibia had a nutrient foramen, and 66.67% of the fibulas lacked a nutrient foramen. The location of the nutrient foramen in the femur was 95.35% at the lower two-thirds. In the tibia, the nutrient foramina were mainly in the upper third (72.15%). In the fibula, the nutrient foramina were mostly in the middle third (66.67%).

**Conclusion:** This study provides more information on morphological and topographic anatomy of the nutrient foramina of long bones of the lower extremity. While techniques such as microvascular bone transfer have become more popular, further research is required to determine the effect of inheritance and race for an anatomical description of bone nutrition.

**Keywords:** Bone, Femur, Tibia, Fibula, Nutrient Foramen

**Received: 9 months before printing; Accepted: 1 month before printing**

Mahdi Hamzehtofigh\*; Mohadeseh Rahimi\*; Parvindokht Bayat, PhD\*\*

### Introduction

From developmental period, the bones adapt to the presence of naturally occurring holes, which are known as nutrient foramen that enables the blood vessels and peripheral nerves to pass through the cortex of the bone<sup>(1-3)</sup>. Nutritional arteries are the main source of blood supply to long bones, which usually meet the need of bones during the growth phase and in the early stages of ossification<sup>(4,5)</sup>. In most cases, the nutrient foramen is directed away from the dominant growing end of the long bone. There are often one-two nutritional arteries that supply blood to long bones. In addition to nutritional arteries, metaphyseal, epiphyseal, and periosteal arteries can deliver nutrients to bones<sup>(6-9)</sup>.

During the early phases of ossification, long bones receive about 80% of their blood flow from the nutritional arteries, and coronary arteries perform this task through the periosteum in case of lack of nutritional arteries<sup>(8,9)</sup>. Bone nutrient supply leads to the survival of osteoblast and osteocytes cells in bone. Moreover, supplying nutrients for bone is vital for bone grafting<sup>(4)</sup>. Complete knowledge about blood flow of long bones is one of the most important success factors in the technique of transplantation and cutting bone in orthopaedic cases. In terms of transplantation technique, the presence of various nutrient foramina on bones helps surgeons perform the grafting while causing no damage to the nutritional arteries<sup>(6,10)</sup>.

\* Student Research Committee, Arak University of Medical Sciences, Arak, Iran.

\*\* Department of Anatomy, Arak University of Medical Sciences, Arak, Iran

#### \* Correspondence

Parvindokht, Bayat (PhD),

Email Address:  
DR.bayat@arakmu.ac.ir

By identifying the exact location of nutrient foramina, which give direction to blood vessels and nerves of the bone, it is possible to perform surgery at these points more carefully to prevent damage to the vessels and nerves. For the first time in Iran, the nutrient foramina, as well as their location, passage, and topography were assessed in the present study. In addition, all bone borders and surfaces were evaluated and observed in terms of the presence of nutrient foramen. The current research provided more information on the morphological anatomy and topography of nutrient foramina of long bones in lower limbs. While techniques such as transfer of microvascular bone are more popular, having information about the anatomical description of these foramina is vital for maintaining blood flow in bone tissue. However, more studies are required to determine the effect of inheritance and race on the anatomical description of this structure.

## Methods

This study was performed on 157 lower limb bones (femur, tibia, and fibula) present in moulage hall in the school of medicine of Arak University of Medical Sciences in 2018. In total, the samples were long bones of the femur (N=65), tibia (N=65) and fibula (N=27), all of which belonged to the Iranian race and their age and gender were unclear. All broken and unnatural bones were excluded from the research. Bones were evaluated in terms of length, direction, transverse diameter at the location of the nutrient foramen, and anteroposterior diameter of the nutrient foramen. On the other hand, the nutrient foramina were assessed regarding the number, direction, location, diameter, as well as distance from the proximal end of the bone and distance from the distal end of the bone. A lens was applied to better observe the samples, and each bone was marked during the evaluation of foramina. In the present study, the diaphyseal

area of each bone was assessed regarding the presence of a nutrient foramen.

The parameters estimated were measured in mm using a ruler and caliper (INSIZE; Digital Caliper code 1114-200A). At first, each bone was divided into three equal parts (upper, middle, lower). In addition, measurement condition was similar for all bones. However, each bone was studied by two individuals separately to avoid errors. To ensure the results, some of the bones were randomly re-measured.

1. Side of each bone (right or left)
2. length of bone (the distance was measured from the highest point from which the sheet passed to the lowest point where another sheet passed, as illustrated in Figure 1)
3. Number of nutrient foramina (even the smallest foramina observed by a lens were considered, as shown in Figure 1)
4. Location of nutrient foramina (the diaphyseal area of bones was divided into three equal parts [upper third, middle third and lower third])
5. Topography of nutrient foramina (place of nutrient foramina was evaluated in terms of the presence of various levels and border or between two borders of the bone)
6. Direction of nutrient foramina (the foramina are directed upward, downward, inward, or outward)
7. Maximum diameter of nutrient foramina
8. Anteroposterior diameter of the bone at the location of nutrient foramina
9. Transverse diameter of the bone at the location of nutrient foramina
10. Distance of the nutrient foramen from the proximal end of the bone (this distance was measured from the highest point where we pass the sheet [proximal point] to the place of the nutrient foramen where a sheet is passed using a ruler and in mm)
11. Distance of the nutrient foramen from the distal point of bone (this distance was measured from the lower point where we passed a sheet [the distal point] to the location of the foramen where a sheet is passed using a ruler and in mm)
12. Foraminal index (FI) is calculated as dividing the distance between proximal end (D) of the bone and nutrient foramen to the total bone length (L), which was ultimately multiplied by 100:  $FI = D/L \times 100$

In addition, it is noteworthy that in bones with more than one foramina, the largest nutrient foramen was regarded in terms of its opening diameter. The foraminal index is measured the same way in other studies.

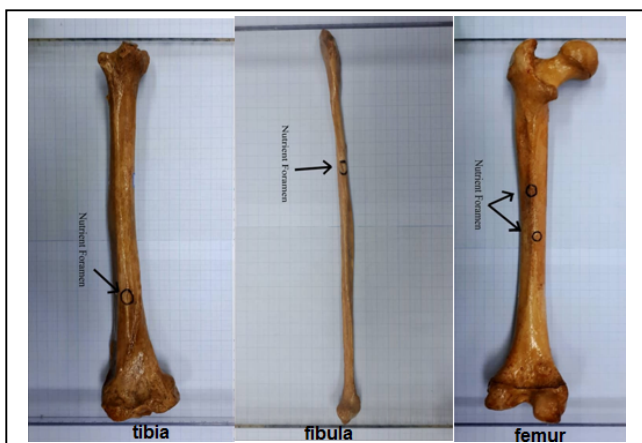


Figure 1. Nutrient Foramina in Femur, Tibia, and Fibula

### Results

According to our findings, the mean length of the femur was 424.1±27.0 mm while the means of tibia and fibula were 360±22.6 mm and 352.5±24.3 mm, respectively. The highest and lowest numbers of nutrient foramina of the femur, tibia, and fibula were reported to be seven-zero, two-zero, and one-zero, respectively. According to Table 1, which shows the location of nutrient foramina, the highest frequency of presence of nutrient foramina (48.84%) was observed in the lower third of the femur. On the other hand, the highest frequency of presence of nutrient foramina (72.15%) was related to the upper third of the tibia. Meanwhile, the highest frequency of the mentioned variable (66.67%) was found in the middle third of the fibula.

Table 1. Location of Nutrient Foramina in the Femur, Tibia, and Fibula Bones in the Iranian Race

Location	Femur	Tibia	Fibula
upper	(4.65%) 8	(72.15%) 44	(11.11%) 1
middle	(46.51%) 80	(26.22%) 16	(66.67%) 6
lower	(48.84%) 84	(1.63%) 1	(22.22%) 2
total	(100%) 172	(100%) 61	(100%) 9

According to Table 2, the location of nutrient foramina in the femur, tibia, and fibula bones was evaluated. Results demonstrated that nutrient foramina were mostly found in the

anterior level in the femur (36.08%). In addition, the nutrient foramina were mainly observed under the Soleal line in the tibia (88.56%). Meanwhile, the main location of the nutrient foramina in the fibula was reported to be between the medial crest and posterior border (55.56%).

Table 2. Topography of Nutrient Foramina in the Femur, Tibia, and Fibula Bones in the Iranian Race

Type of Bone	Topography	Number (%)
Femur	Anterior Surface	62 (36.08%)
	Medial Surface	13 (7.55%)
	Lateral Surface	3 (1.74%)
	Popliteal Surface	22 (12.79%)
	Superoposterior Surface	4 (2.32%)
	Linea Aspera	59 (34.30%)
	Medial Lip	7 (4.06%)
	Lateral Lip	2 (1.16%)
	Tibia	Below the Soleal line
On the Soleal line		3 (4.91%)
lateral the vertical line		2 (3.27%)
On the interosseous border		1 (1.63%)
On the medial border		1 (1.63%)
Fibula	Anterior surface	1 (11.11%)
	On the medial crest	2 (22.22%)
	Between medial crest and interosseous border	1 (11.11%)
	Between medial crest and posterior border	5 (55.56%)

According to the results, most nutrient foramina in the femur had a downward direction (69.21%) while the majority of the nutrient foramina in the tibia had an upward direction (98.37%). In the fibula, the highest number of nutrient foramina had an upward direction (77.78%). According to Table 3, the anteroposterior diameter at the location of the nutrient foramen was measured in millimeters.

Table 3. Anteroposterior Diameter of Bones at the Location of Nutrient Foramen in the Femur, Tibia, and Fibula in the Iranian Race

Anteroposterior Diameter(mm)	Femur	Tibia	Fibula
Minimum	19	23.5	11.6
Maximum	64.6	40.2	16.9
Mean ± std.Deviation	41.8±32.2	31.8±11.8	13.7±1.6

According to Table 4, the transverse diameter of bones at the location of the nutrient foramen was estimated in millimeters.

**Table 4. Transverse Diameter of Bones at the Location of Nutrient Foramen in the Femur, Tibia, and Fibula in the Iranian Race**

Transverse Diameter(mm)	Femur	Tibia	Fibula
Minimum	19.4	17.3	9.7
Maximum	83	40.3	12.6
Mean ± std.Deviation	51.2±44.9	28.8±16.2	10.7±0.9

## Discussion

Nutrient foramina enable the passage of nutritional arteries. Studies conducted in this field have shown the difference in the location of nutrient foramina of various races. In the present study, which was conducted on 64 femurs, 65 tibias, and 27 fibulas, the mean lengths of the mentioned long bones were estimated at 424.1 mm, 360 mm, and 352.5 mm, respectively. The number of nutrient foramina in the femur is different and is reported to be in the range of zero-seven. Researchers with similar studies have even reported up to nine nutrient foramina in this bone<sup>(11)</sup>. In the current research, 36.08% and 34.3% of the nutrient foramina in the femur were found at the anterior level and on the Linea aspera, respectively. Relatively similar results were obtained by Murlimanju B<sup>(12)</sup> in a research on Indian people (52.41% nutrient foramina on the Linea aspera) and by Shahwani (13) in a study on the Pakistani people (51.91% of the nutrient foramina on the Linea aspera).

In the present study, 88.56% of the nutrient foramina in the tibia were under the Soleal line, which was in congruence with the findings of Murlimanju B, which were indicative of 49.27% frequency of presence of nutrient foramina under the Soleal line in Indian people. In the current study, the majority of nutrient foramina (72.15%) were in the upper third, which is in line with the results obtained by Kamath V (74.65%) (14), Vadhel CR (92.6%)<sup>(15)</sup> and Roul B (91.9%) (16), which is indicative of lack of presence of nutrient foramina in the lower third. These results are significantly crucial surgically. In the

present research, the opening of most nutrient foramina (69.21%) had a downward direction (toward the lower end of the bone). In studies by Bilodi AKS and Reddy BS on bones of various races, all nutrient foramina had an upward direction<sup>(8)</sup>, which is inconsistent with our findings. This lack of consistency between the results might be due to the evaluation of four directions in the present research and assessment of only the upward or downward direction in the mentioned studies.

In line with our results, studies conducted in India reported the presence of two nutrient foramina in most femurs. Meanwhile, the majority of femurs (63.8%) in a study in Brazil had one nutrient foramen. There was a higher frequency of presence of three nutrient foramina in the current research, compared to other studies. For example, Roul B and Goyal M<sup>(16)</sup> reported the frequency of presence of three nutrient foramina to be 13.51%, which is comparable to our findings. In addition, Pereira G et al. conducted a study on 142 femurs of Brazilian people, marking that 140 cases (98.6%) had one nutrient foramen<sup>(1)</sup>. In another research by Ankolekar VH et al. on 50 tibias of Indian people, 89.5% and 10.5% of the bones had one and two nutrient foramina, respectively<sup>(6)</sup>, which is in congruence with our findings.

In a study on 189 fibulas collected from various countries, Bilodi Aks et al. reported that 85% of the bones had one nutrient foramen while 13% and 2% had two and no nutrient foramina, respectively<sup>(8)</sup>, which is inconsistent with our findings since the majority of fibulas in the current research had no nutrient foramina. Given the performing of the current research in the moulage hall of the school of medicine of Arak University of Medical Sciences, we had access to a limited number of bones (N=157). However, other studies have been conducted on sample sizes relatively equal to our sample size<sup>(8,11)</sup>. It is noteworthy that these results have been obtained in Iran for the first time and there has been no similar research to compare other Iranian ethnicities.

## Conclusion

Determining the exact location of nutrient foramina is significantly important in surgeries

on bones. In addition, having accurate knowledge about the precise location and distribution of the nutrient foramina is crucial to prevent damage to the nutritional arteries and maintain blood flow during various surgical procedures. It has been reported that inheritance and race play a significant role in the distribution of these foramina. According to the results of the present study, there was a significant difference between the Iranian race and other races in this regard. It is suggested

that future studies be performed in other provinces of Iran.

### Acknowledgments

Hereby, we extend our gratitude to the student research committee and the deputy for research and technology of Arak University of Medical Sciences for approving and financing the project (code: 3088).

## References

- Pereira G, Lopes P, Santos A, Silveira F. Nutrient foramina in the upper and lower limb long bones: morphometric study in bones of Southern Brazilian adults. *Int J Morphol*. 2011;29(2):514-20.
- Malukar O, Joshi H. Diaphyseal nutrient foramina in long bones and miniature long bones. *Natl J Integr Res Med*. 2011;2(2):23-6.
- Joshi P, Mathur S. A comprehensive study of nutrient foramina in human lower limb long bones of Indian population in Rajasthan State. *Galore International Journal of Health Sciences and Research*. 2018;3(3):34-42.
- Sinha P, Mishra SR, Kumar P, Gaharwar A, Sushobhana. Morphology and topography of nutrient foramina in fibula. *Annals of International Medical and Dental Research*. 2016;2(6):7-12.
- Ukoha UU, Umeasalugo KE, Nzeako HC, Ezejindu DN, Ejimofor OC, Obazie IF. A study of nutrient foramina in long bones of Nigerians. *Natl J Med Res*. 2013;3(4):304-8.
- Ankolekar VH, Quadros LS, D'souza AS. Nutrient foramen in tibia—A study in coastal region of Karnataka. *IOSR Journal of Dental and Medical Science*. 2013;10(3):75-9.
- Zahra SU, Kervancioğlu P, Bahşi İ. Morphological and topographical anatomy of nutrient foramen in the lower limb long bones. *Eur J Ther*. 2018;24(1):36-43.
- Bilodi AKS, Reddy BS. A study on nutrient foramina of fibula, its medicolegal aspect and clinical importance in dentistry. *World J Pharm Pharm Sci*. 2014;3(2):2133-44.
- Bhat D. Study of nutrient foramina of adult femora with its correlation to length of the bone. *Int J Anat Res*. 2015;3(4):1573-7.
- Afzal E, Masood A, Sherin F, Ullah N. Diaphyseal nutrient foramina in dried human adult long bones of upper and lower limbs in Pakistan. *Adv Basic Med Sci*. 2017;1(1):30-4.
- Gupta RK, Gupta AK. A study of diaphyseal nutrient foramina in human femur. *Int J Res Med Sci*. 2016;4(3):706-12.
- Murlimanju B, Prashanth K, Prabhu LV, Chettiar GK, Pai MM, Dhananjaya K. Morphological and topographical anatomy of nutrient foramina in the lower limb long bones and its clinical importance. *Australas Med J*. 2011;4(10):530-7.
- Shahwani MB, Ahmad MA, Kakar LM, Khan MN. Significance of morphometric anatomy of diaphyseal nutrient foramen in dried Pakistani femurs and its clinical applications in microvascular bone graft. *P J M H S*. 2017;11(1):352-5.
- Kamath V, Asif M, Bhat S, Avadhani R. Primary nutrient foramina of tibia and fibula and their surgical implications. *Indian J Clin Anat Physiol*. 2016;3(1):41-4.
- Vadhel CR, Kulkarni MM, Gandotra AR. Anatomy of nutrient foramen of tibia—a study from Gujarat region. *Indian J Clin Anat Physiol*. 2015;2(1):6-10.
- Roul B, Goyal M. A study of nutrient foramen in long bones of inferior extremity in human being. *Int J Adv Res*. 2015;3(4):945-8.